

7 laboratories participated. In one gastrointestinal stromal tumour (GIST), good or moderate staining was obtained in 6 laboratories. However, in another GIST, good staining was obtained with one protocol only, while three protocols gave acceptable staining. Dako's polyclonal antibody appeared most reliable. Less optimal stainings appeared when the antibody was too diluted. Another cause for poor stainings appeared to be insufficient demasking (insufficient heating time, buffer pH too low).

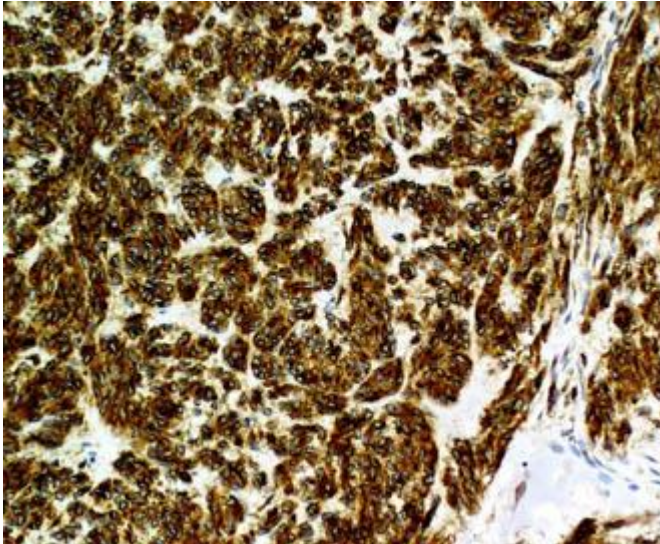


Fig. 1a
Laboratorium A. One case of GIST stained for CD117 using a good protocol (2). All tumour cells are strongly stained.

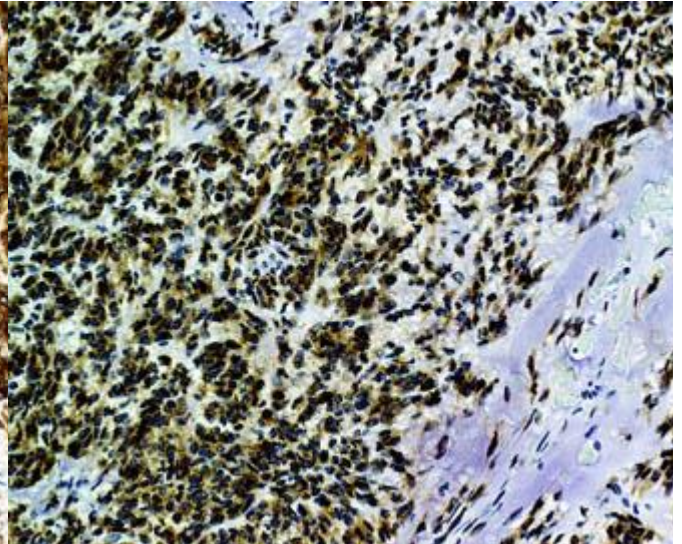


Fig. 1b
Laboratorium B. GIST (same tumour and field as in Fig. 1a) stained for CD117 using a less optimized protocol. All tumour cells in this case are strongly stained. However, compare with Fig. 2a and b.

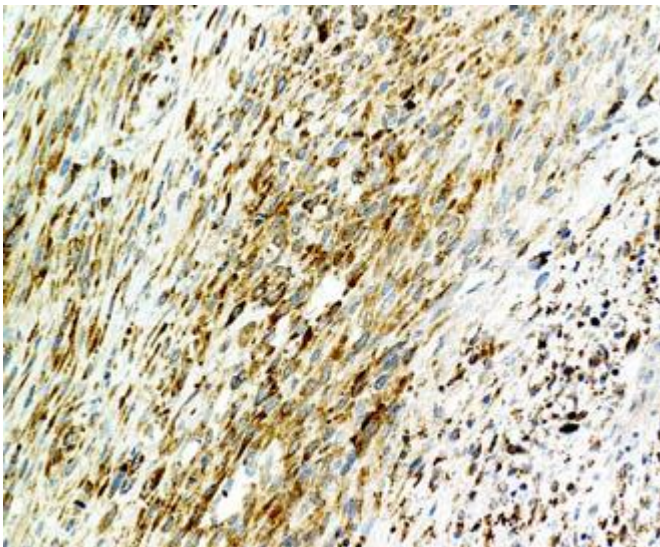


Fig 2a
Laboratorium A. Another case of GIST stained for CD117 using a good protocol (2). Weaker staining than the tumour in Fig. 1a is seen.

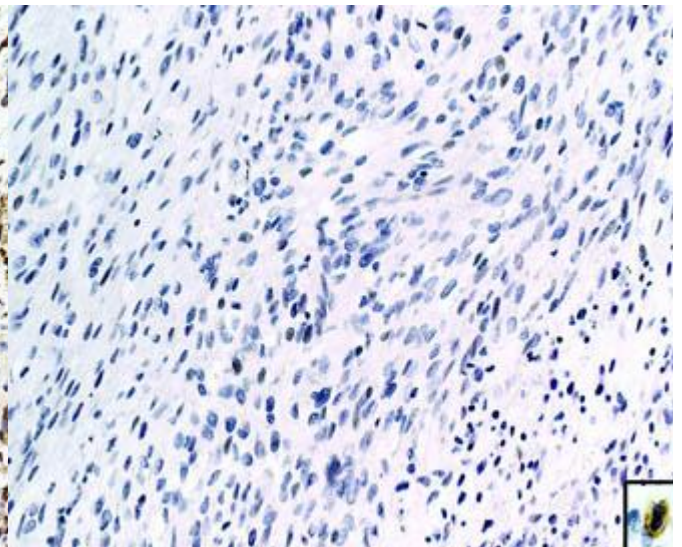


Fig. 2b
Laboratorium B. GIST (same tumour and field as in Fig. 2a) stained for CD117. The tumour is completely unstained. Inset: High magnification of a strongly stained mast cell occurring in another in the tumour, giving the impression of a positive internal control.

SN/MV/LE 1-4-2007