

The slide to be stained for CD99 comprised:

1. Ewing sarcoma, 2. Peripheral primitive neuroepithelial tumour (pPNET),
3. Granulosa cell tumour, 4. Synovial sarcoma, 5. Tonsil, 6. Liver.



Criteria for assessing a CD99 staining as optimal included: A moderate to strong distinct predominantly membranous staining of basal and parabasal squamous epithelial cells and lymphocytes in the tonsil, and a moderate to strong distinct predominantly membranous staining the Ewing sarcoma, pPNET, synovial sarcoma and granulosa cell tumour. No reaction should be seen in the liver.

41 laboratories submitted stains. At the assessment 5 achieved optimal staining (12 %), 13 good (32 %), 12 borderline (29 %) and 11 (27 %) poor staining.

The following Abs were used:

mAb clone 12E7 (DakoCytomation, n=35)

mAb clone H036-1.1 (Cell Marque, n=2; Ventana, n=2; Novocastra, n=1)

mAb clone 0-13 (Signet, n=1)

In this assessment optimal staining could only be obtained with the mAb clone 12E7. However, only 5 out of 35 (14 %) using this clone achieved an optimal staining.

In the optimal protocols with clone 12E7, all used HIER with Tris-EDTA/EGTA pH 9 as the heating buffer. The mAb clone 12E7 was typically used in the range of 1:25 – 1:100.

All stains assessed as suboptimal were either generally too weak or false negative in one or more of the specimens in the multi-block. Almost all laboratories were able to detect CD99 in the Ewing sarcoma, whereas the synovial sarcoma, the pPNET and especially the granulosa cell tumour were only weakly labelled or completely negative with suboptimal protocols.

In the optimal staining only, basal and parabasal squamous epithelial cells of the tonsil were identified displaying a distinct membranous staining, indicating that these cells might serve as an appropriate positive control for the detection of CD99.

The most frequent causes of insufficient stainings were (often in combination):

- Inappropriate choice of HIER buffer (esp. citrate pH 6)
- Omission of epitope retrieval
- Too low concentration of the primary Ab
- Inappropriate choice of primary Ab.

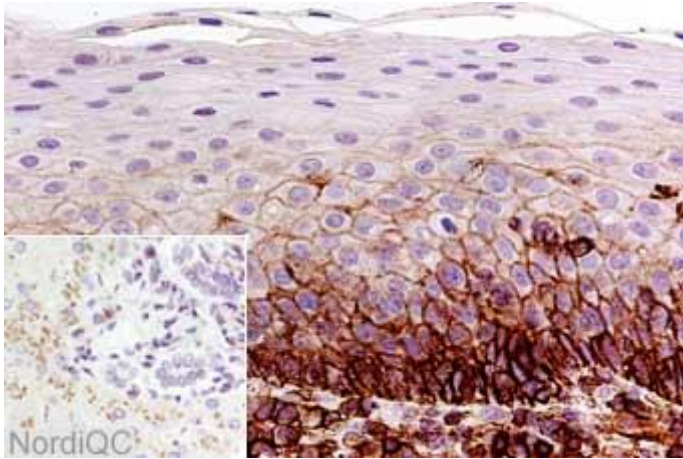


Fig. 1a
Optimal CD99 staining of the tonsil. A moderate to strong membranous staining is seen in the basal and parabasal cells of the squamous epithelium. Practically all lymphocytes are positive. No staining reaction is seen in hepatocytes and bile duct epithelium (inset).

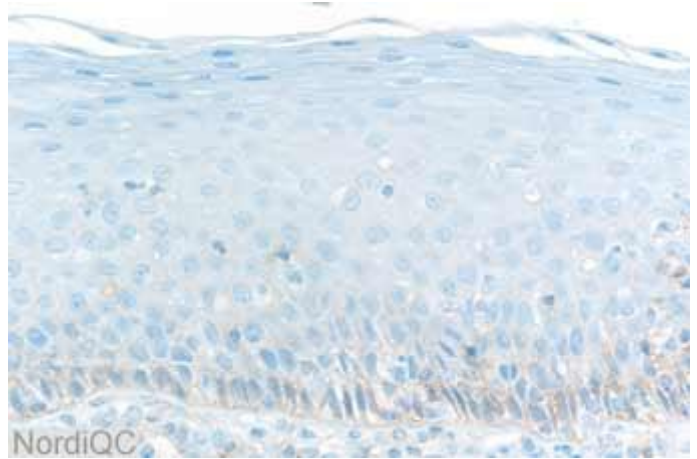


Fig. 1b
Insufficient CD99 staining of the tonsil. Only a weak reaction of the basal and parabasal cells is seen in the squamous epithelium. The lymphocytes are virtually negative.

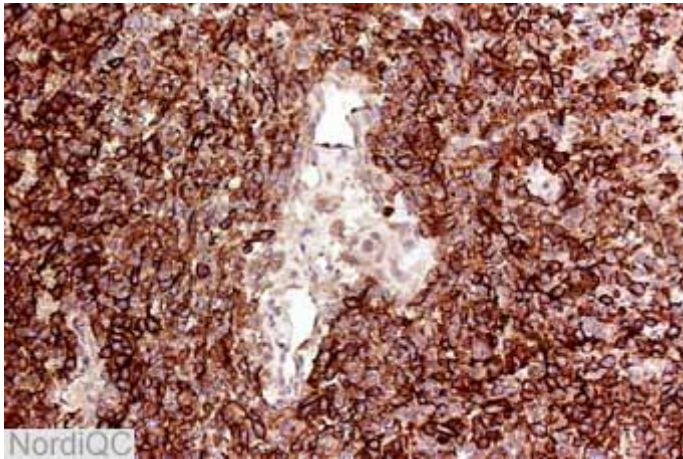


Fig. 2a
Optimal CD99 staining of the Ewing sarcoma. All the neoplastic cells are strongly labelled. A weak reaction is seen in the endothelial cells (same protocol as used in Fig. 1a).

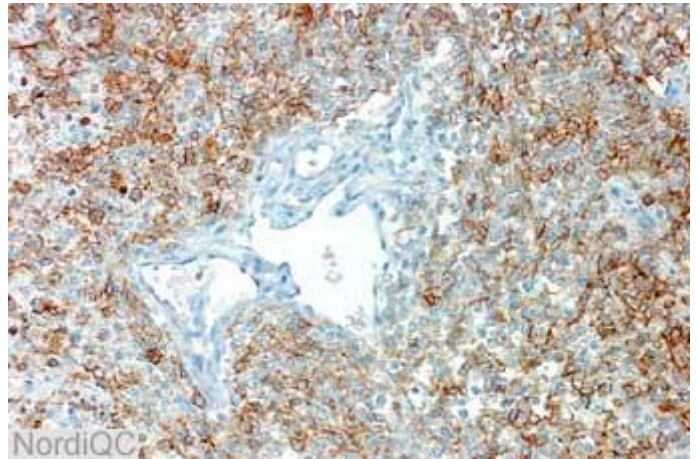


Fig. 2b
CD99 staining of the Ewing sarcoma using an insufficient protocol (same protocol used in Fig. 1b). The staining reaction is acceptable, though somewhat weaker than in Fig. 2a. However, compare Fig. 3b.

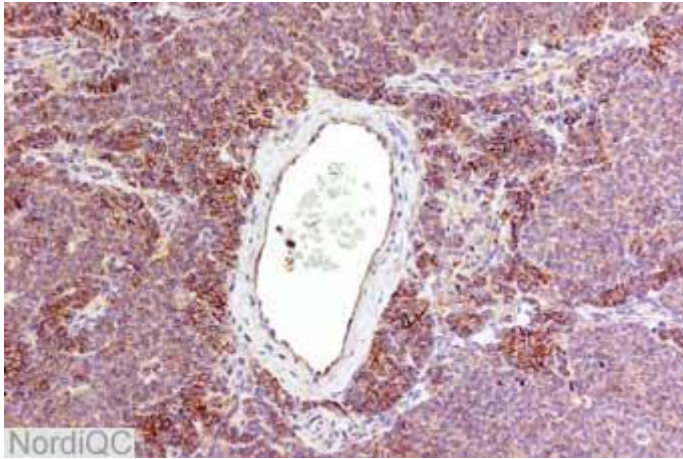


Fig. 3a
Optimal CD99 staining of the granulosa cell tumor.
A weak to moderate membranous staining is seen in the majority of the cells (same protocol as used in Fig. 1a).

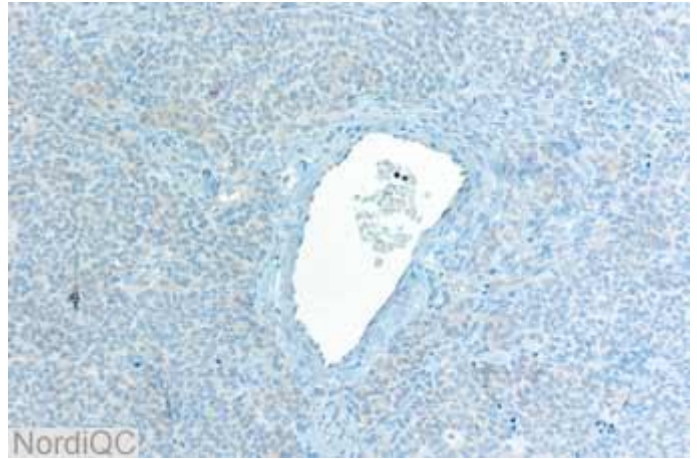


Fig. 3b Insufficient CD99 staining of the granulosa cell tumor.
The neoplastic cells are virtually negative (same protocol used in Fig. 1a and 1b).

SN/MV/LE 28-11-2004