

The slides to be stained for CD117 comprised:  
1: appendix, 2-3: GIST (small intestine), 4: myeloid sarcoma (breast), 5: liver.

Criteria for assessing a CD117 staining as optimal included:  
Distinct staining reaction of the appendiceal Cajal cells and breast epithelium, the tumour cells of the two GISTs and the myeloid sarcoma without any background staining, particularly no staining of the smooth muscle cells or liver cells.

56 laboratories submitted stainings. At the assessment, 20 laboratories achieved optimal staining (36%), 15 good (27%), 14 borderline (25%), and 7 poor staining (13%).

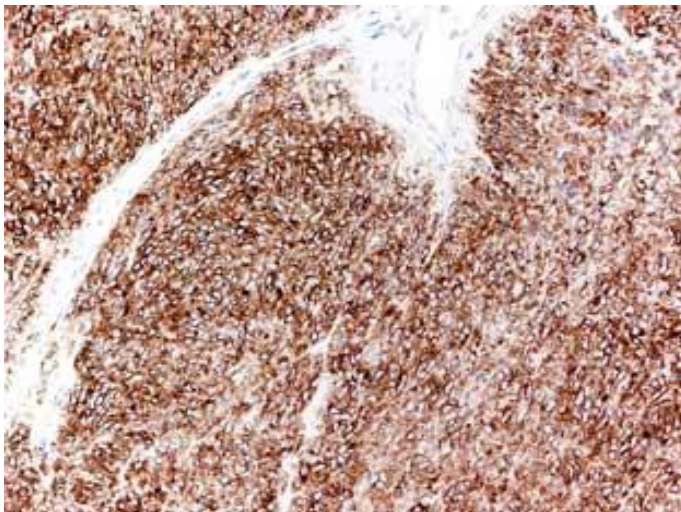
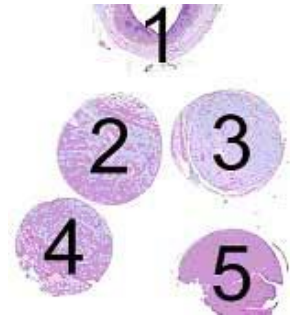
49 used **pAb A4502** (DakoCytomation), 3 used **pAb sc168** (Santa Cruz), 2 used **mAb T595** (Novocastra), 1 used **mAb RB1518** (Neomarkers) and 1 used **pAb 790-2936** (Ventana).

Mandatory for an optimal CD117 staining reaction in this assessment was the use of **pAb A4502** in combination with an efficient HIER protocol. All but 3 used Tris/EDTA or Tris/EGTA pH 9 as heating buffer, one used TRS (DakoCytomation, pH 6) and two used Citrate pH 6.

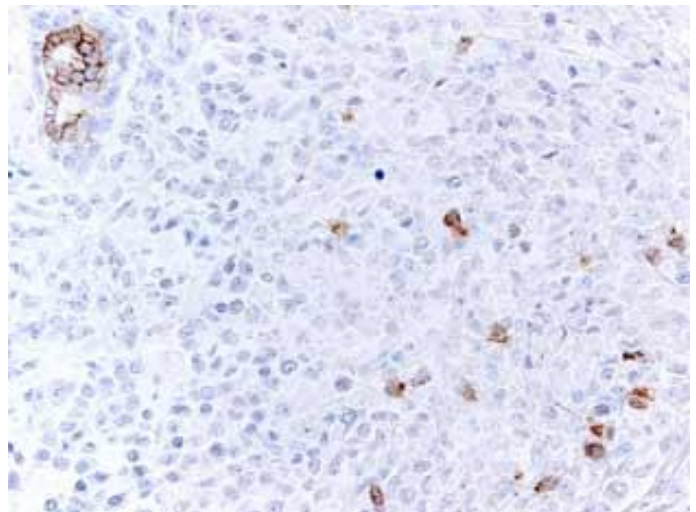
The most frequent primary Ab dilution using the alkaline heating buffer was 1:200 - 1:500. When a heating buffer pH 6 was used, either the Ab was more concentrated or the incubation time prolonged. Irrespective of lot number of the pAb A4502, it was possible to obtain an optimal staining.

The most frequent causes of insufficient stainings (often in combination) were:

- Less successful primary Ab
- A too low primary Ab concentration (particularly when a less sensitive protocol was used)
- A too high primary Ab concentration
- Missing or insufficient HIER.



**Fig. 1a**  
Optimal staining of CD117 in a GIST (pAb A4502). All tumour cells show strong cytoplasmic reaction with membrane enhancement. The endothelial cells (upper part of the photo) are unstained.



**Fig. 1b**  
Optimal staining of CD117 (pAb A4502) in a breast with acute myeloid leukaemia. The epithelial cells show distinct membrane staining. Scattered tumour cells are positive.

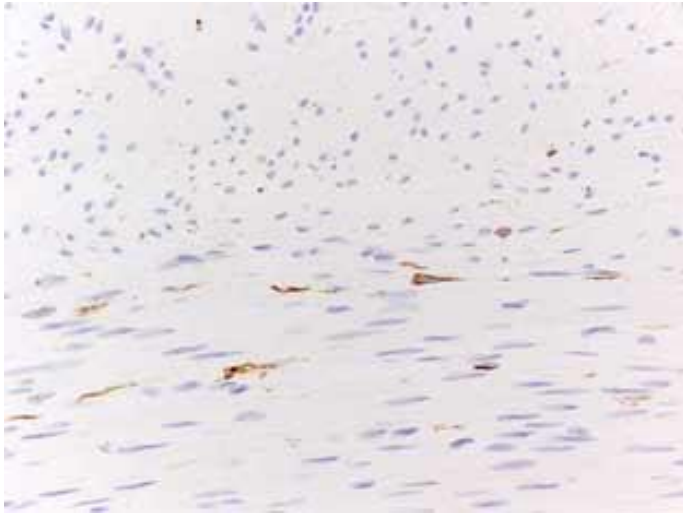


Fig. 1c  
Optimal staining of CD117 (pAb A4502) demonstrating Cajal cells in appendiceal muscularis propria. The smooth muscle cells are unstained.

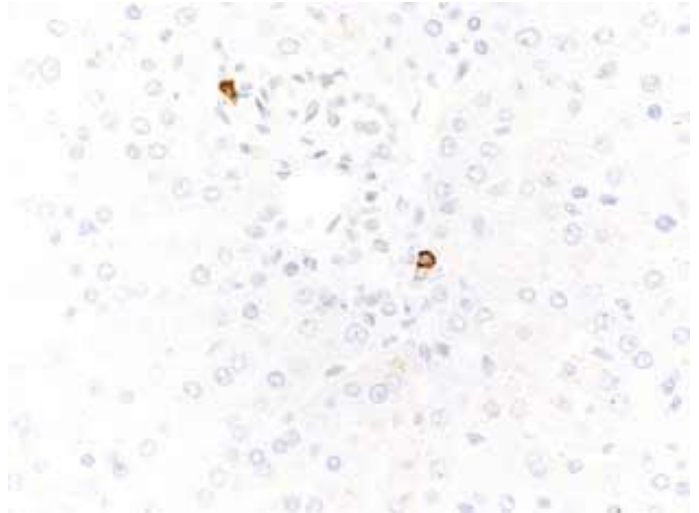


Fig. 1d  
Optimal staining of CD117 (pAb A4502) in a liver. Only portal tract mast cell should stain.

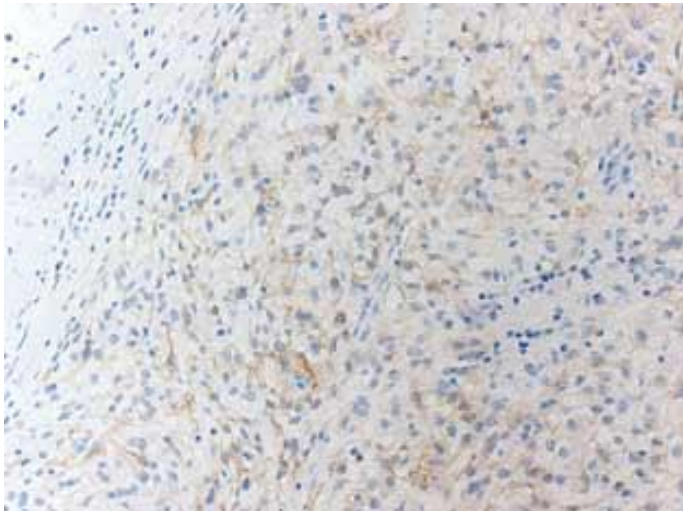


Fig. 2a  
Insufficient staining of CD117 in a GIST (same field as in Fig. 1a). The tumour cells are weakly stained. Too dilute Ab + insufficient HIER.

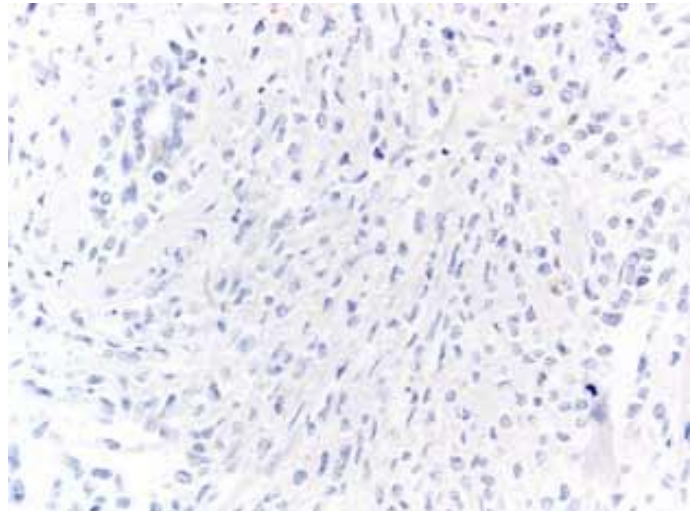


Fig. 2b  
Insufficient staining of CD117 in a breast AML (same field as in Fig. 1b). The epithelial cells as well as the tumour cells are unstained. Too dilute Ab + insufficient HIER.

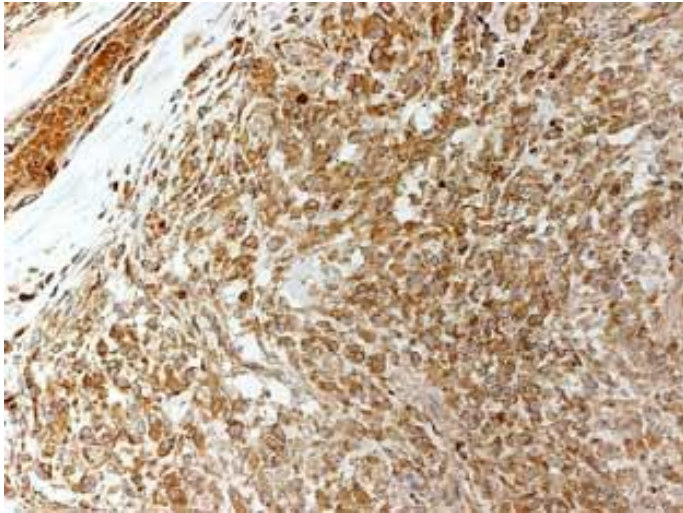


Fig. 3a  
Insufficient staining of CD117 in a GIST using pAb sc168 (same field as in Fig. 1a). Apparently strong staining of all tumour cells. However, the endothelium and serum (upper left corner) is strongly stained as well. Also compare Fig. 3b-d.

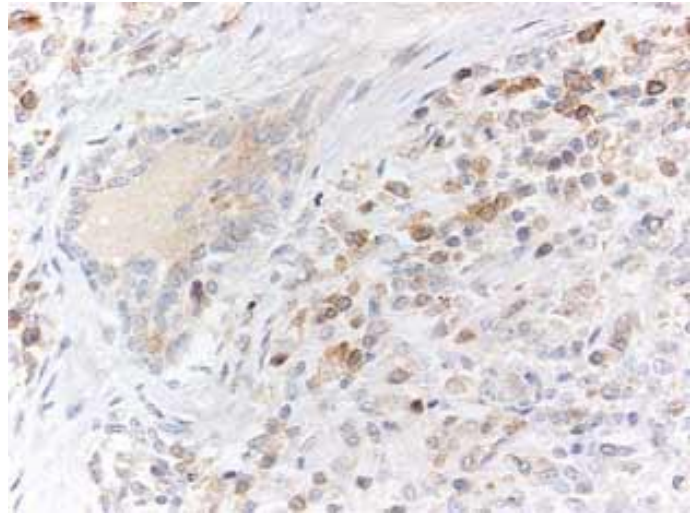


Fig. 3b  
Insufficient staining of CD117 in a breast AML using sc168 (same field as in Fig. 1b). Most tumour cells are stained. However this is a false positive staining (cytoplasmic staining both in tumour cells, lymphocytes and endothelial cells).

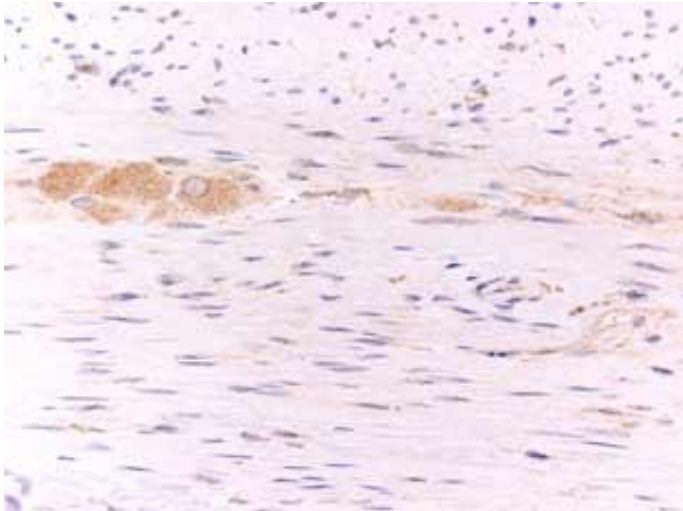


Fig. 3c  
Insufficient staining of CD117 in appendix using pAb sc168 (same field as in Fig. 1c). Moderate staining of neurons and weak staining of smooth muscle cells while the Cajal cells are difficult to identify.

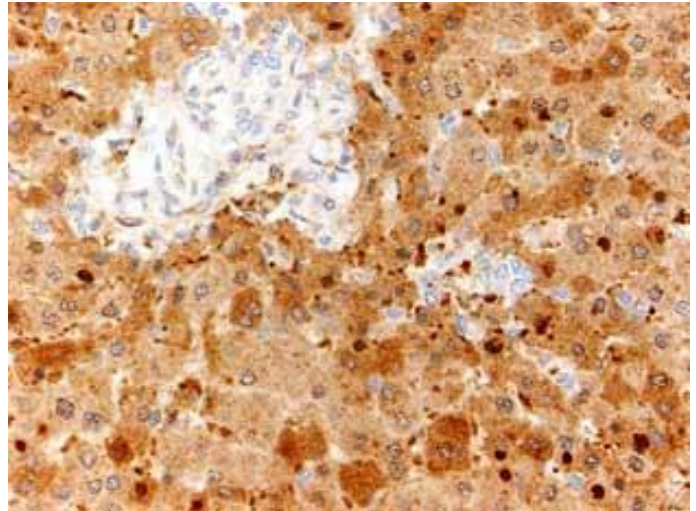


Fig. 3d  
Insufficient staining of CD117 in a liver using pAb sc168 (same field as in Fig. 1d). Strong staining of liver cells and various cells in the portal tract.

SN/MV/LE 21-4-2006